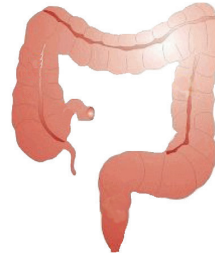



EndoSoft Surgery Center

135 Broadway
Schenectady, New York 12305

Patient Name: John Smith
Date of Birth: 09/15/1950
Record Number: 0159834
Date / Time of Procedure: 11/11/2017, 07:56:49
Referring Physician: Frank Black, MD
Endoscopist: Debbie Doe, MD



PROCEDURE PERFORMED: Colonoscopy - complete to terminal ileum.

INDICATIONS FOR EXAMINATION:

Blood in stool.

FINDINGS:

Normal to the terminal ileum, Internal hemorrhoids

ENDOSCOPIC DIAGNOSIS:

Normal colon, Internal hemorrhoids without complication

RECOMMENDATIONS:

Follow-up procedure in 10 years
 Continue current medications
 High fiber diet
 Await biopsy results

INSTRUMENTS: CF 180 254875 **QUALITY OF BOWEL PREP:** Adequate
MEDICATIONS: Versed 3mg IVP, Fentanyl 100 mg IV
BOSTON BOWEL PREP SCORE: **RIGHT COLON:** 3 **TRANSVERSE COLON:** 3 **LEFT COLON:** 3 **TOTAL:** 9
WITHDRAWAL TIME: 00:08 **EXTENT OF EXAM:** Terminal ileum
LANDMARKS IDENTIFIED: Terminal ileum
VISUALIZATION: Good **TOLERANCE:** Good **COMPLICATIONS:** None **LIMITATIONS:** None

PROCEDURE TECHNIQUE: A physical exam was performed. Informed consent was obtained from the patient after explaining all of the risks (perforation, bleeding, infection and adverse effects to the medication), benefits and alternatives to the procedure which the patient appeared to understand and so stated. The patient was connected to the monitoring devices and placed in the left lateral position. Continuous oxygen was provided with a nasal cannula and IV medicine administered through an indwelling cannula. After adequate conscious sedation was achieved, a digital exam was performed and the colonoscope introduced into the rectum and advanced under direct visualization to the terminal ileum.

The terminal ileum was identified by visual landmarks. The scope was subsequently removed slowly while carefully examining the color, texture, anatomy and integrity of the mucosa on the way out. In the rectum, the scope was retroflexed to evaluate for internal hemorrhoids and anorectal pathology. The patient was subsequently transferred to the recovery area in satisfactory condition.

CPT Code:

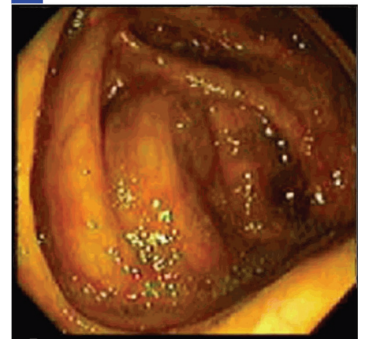
45384 Colonoscopy, flexible, proximal to splenic flexure; with removal of tumor(s), polyp(s), or other lesion(s) by hot biopsy forceps or bipolar cautery.

ICD 10 Codes:

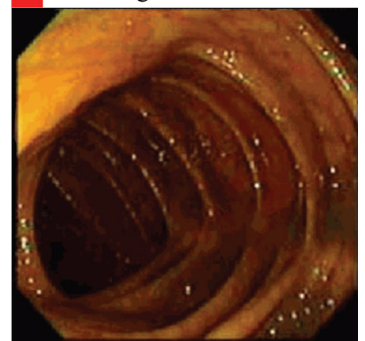
R19.5 Blood in stool
 K64.8 Internal hemorrhoids without complication

Signature: _____ Debbie Doe, MD

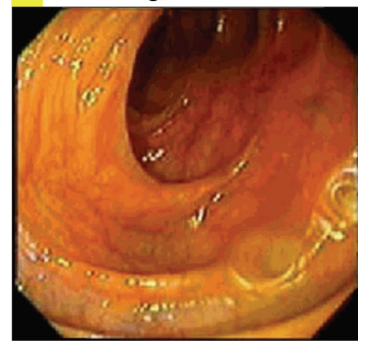
1 Cecum



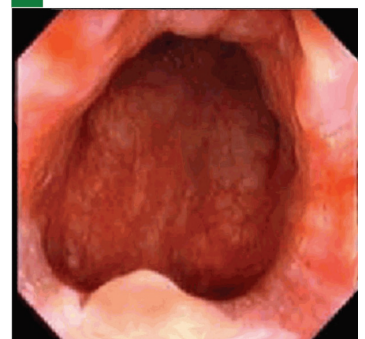2 Ascending Colon



3 Descending Colon



4 Internal Hemorrhoids



Dr. Debbie Doe
EndoSoft Surgery Center
135 Broadway
Schenectady, NY 12144

November 11, 2017

Dr. Frank Black
1234 Main Street
Schenectady, NY 12144

RE: John Smith 11/11/2017
DOB: 09/15/1950

Dear Dr. Black:

Today an endoscopic procedure was performed on your patient John Smith.

Following is a synopsis of the endoscopy report and my initial recommendations:

Procedure Performed:

Colonoscopy - Complete to terminal ileum

Indications:

Blood in stool.

Findings:

Normal colon to the Terminal ileum.
Internal Hemorrhoids.

Diagnosis:

Normal Colon.
Internal Hemorrhoids.

Recommendations:

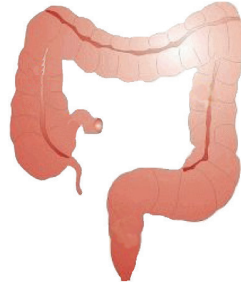Follow-up procedure in 10 years
Continue Current Medications.
High fiber diet.
Await biopsy results.

Thank you for the opportunity to assist you in the care of this patient. The findings were discussed with Mr. Smith today along with the recommendations and follow up arrangements.

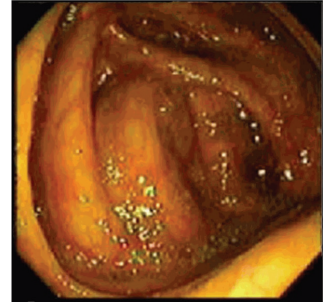
Please feel free to contact me if I can be of any further assistance.

Sincerely,

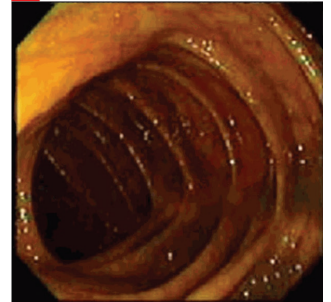
Debbie Doe, MD



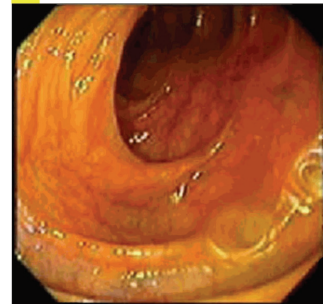1 Cecum



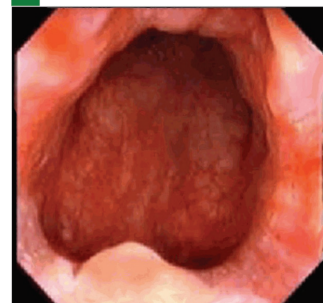2 Ascending Colon



3 Descending Colon



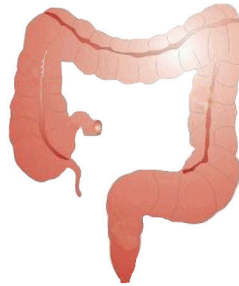4 Internal Hemorrhoids



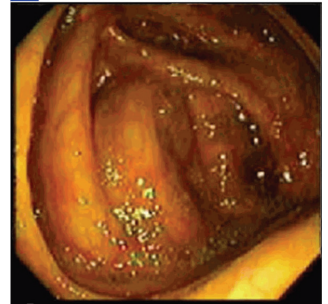


EndoSoft Surgery Center
135 Broadway
Schenectady, NY 12144

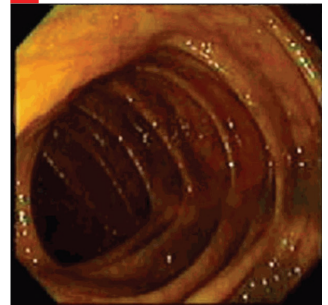
Patient Name: John Smith
Date of Birth: 09/15/1950
Record Number: 0159834
Date / Time of Procedure: 11/11/2017, 07:56:49
Referring Physician: Frank Black, MD
Endoscopist: Debbie Doe, MD



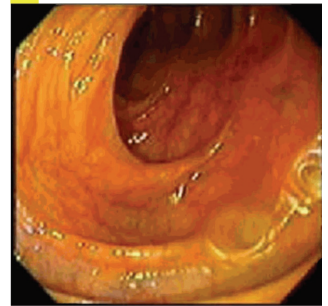
1 Cecum



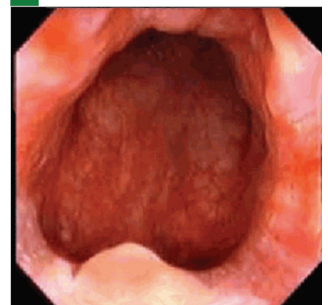2 Ascending Colon



3 Descending Colon



4 Internal Hemorrhoids



PROCEDURE PERFORMED:

Colonoscopy - complete to terminal ileum.

INDICATIONS FOR EXAMINATION

Blood in stool.

Tissue Submitted

Jar 1. biopsy from the ascending colon to exclude Crohn's disease.

FINDINGS:

Normal to the terminal ileum
Internal hemorrhoids

ENDOSCOPIC DIAGNOSIS:

Normal colon
Internal hemorrhoids

RECOMMENDATIONS:

Follow-up procedure in 10 years
Continue current medications
High fiber diet
Await biopsy results

Signature: _____ Debbie Doe, MD

CPT Code:

45384 Colonoscopy, flexible, proximal to splenic flexure; with removal of tumor(s), polyp(s), or other lesion(s) by hot biopsy forceps or bipolar cautery.

ICD Code:

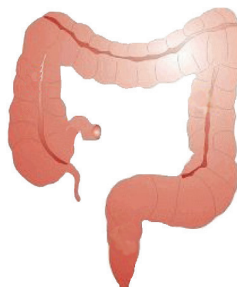R19.5 Blood in stool



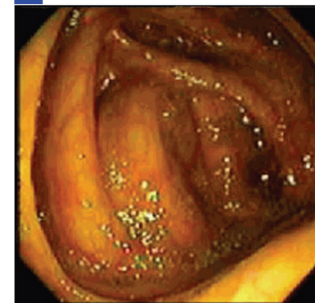
EndoSoft Surgery Center

135 Broadway
Schenectady, NY 12144

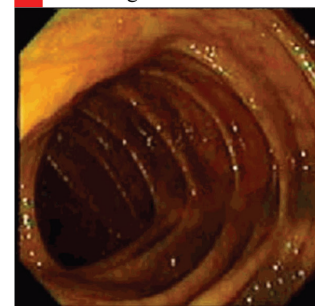
Patient Name: John Smith
Date of Birth: 09/15/1950
Record Number: 0159834
Date / Time of Procedure: 11/11/2017, 07:56:49
Referring Physician: Frank Black, MD
Endoscopist: Debbie Doe, MD



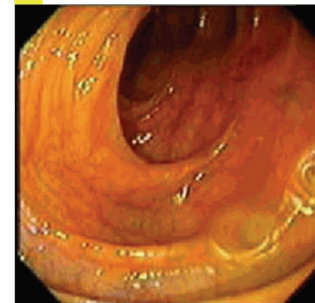1 Cecum



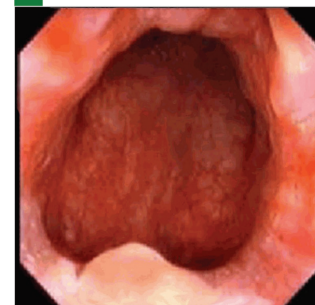2 Ascending Colon



3 Descending Colon



4 Internal Hemorrhoids



You have had the following procedure performed:

Colonoscopy - Complete to terminal ileum

To aid in the prevention of complications, please follow the instructions given below:

Tylenol. No Aspirin or NSAID such as Motrin, Advil, Aleve, or any other Ibuprofen for 5 days.
Do NOT drink alcoholic beverages for 24 hours.
Do NOT drive or operate machinery for the remainder of today.
Do NOT make major decisions, sign contracts, etc. for 24 hours.

Discharged To:

Home

Prescriptions Given to Patient:

None

Appointment Information:

Call for an appointment with Dr. Frank Black in 2 weeks.

Additional Written Instructions Provided to Patient:

None

You should call your doctor, Dr. Frank Black (518)831-8000 , if you experience any rectal bleeding, unusual pain, fever, dizziness, or any other problems.

If you have difficulty contacting your physician, call

EndoSoft, LLC

135 Broadway, Schenectady, NY, 12305
Tel: (518) 831-8000

Instructions on this form have been reviewed with John Doe and escort.

Physician Signature: Debbie Doe, MD Date/Time: 11/11/2017, 07:56:49 AM

I have received a copy and understand the instructions and follow-up medical care.

Patient Signature: John Smith Date/Time: 11/11/2017, 07:56:49 AM

Patient Representative Signature: Jane Smith Doe Date/Time: 11/11/2017, 07:56:49 AM