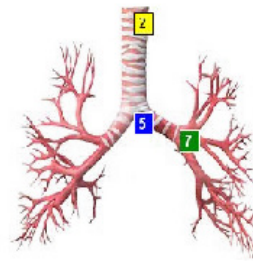




EndoSoft Surgery Center
 135 Broadway
 Schenectady, NY 12144

Patient Name: Robert Smith
Date of Birth: 09/15/1950
Record Number: 0159834
Date / Time of Procedure: 5/18/2017, 07:56:49
Referring Physician: Frank Black, MD
Pulmonologist: Debbie Doe, MD



PROCEDURE PERFORMED: Flexibility bronchoscopy

INDICATIONS FOR EXAMINATION: Large airway obstruction in the left main stem for one month.

INSTRUMENTS: Loaner
MEDICATIONS: Demerol 25 mg, Versed 1 mg
VISUALIZATION: Good **TOLERANCE:** Good **COMPLICATIONS:** None
EXTENT OF EXAM: All segments visualized to subsegmental
LIMITATIONS: None

PROCEDURE TECHNIQUE: Flexible bronchoscopy: A physical exam was performed and an informed consent was obtained from the patient after explaining the risks, (pneumothorax, life threatening bleeding, infection and adverse effects due to medications) benefits and alternatives to the procedure which the patient appeared to understand and so stated. The patient was connected to the monitoring devices. Continuous oxygen was provided with a nasal cannula and IV medicine administered through an indwelling IV catheter. Lidocaine 2%, viscous lidocaine, Demerol 25 mg, Versed 1 mg were used for local anesthesia and conscious sedation. The bronchoscope was inserted and the airway examined.

FINDINGS: Extrinsic compression stricture begins left mainstem bronchus to the left lower lobe extending for the length of 3cm. Scope could be advanced beyond the stricture. The estimated diameter of the lumen was 8mm.

Simple weblike stricture begins LUL entrance with 70% stenosis. Scope could not be advanced beyond the stricture. The estimated diameter of the lumen was 4mm. This was estimated using the scope diameter comparison technique. Diffuse erythema and friable tissue submucosal inflammation was located in the LUL entrance with 80% stenosis.

PULMONOLOGIST DIAGNOSIS: Malignancy, primary lung, small cell in left main stem. Benign stricture, radiation fibrosis in the LUL entrance. Small cell carcinoma of the lung.

RECOMMENDATIONS:
 Follow-up with your Primary Care provider in 2 weeks

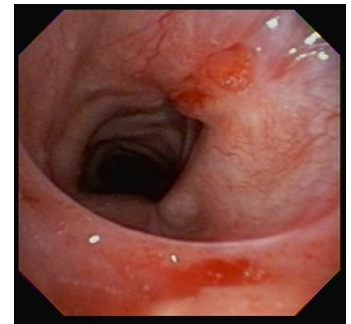
Signature: _____ Debbie Doe, MD

ICD 10 Codes:
 C34.80 Malignant neoplasm of overlapping sites of unspecified bronchus and lung

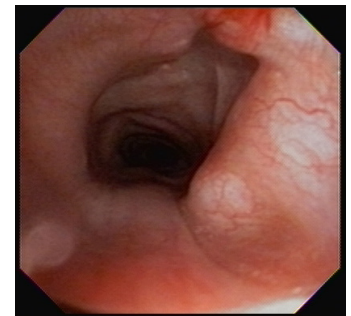
CPT Code:
 31622 Bronchoscopy

G Codes:
 G8907

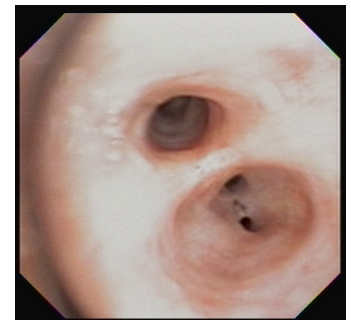
1 Right Lower Lobe Entrance



2 Left Mainstem



3 Left Lower Lobe



4 Left Upper Lobe

